6

Morbidity and Mortality

Sharon L. Deem, Ellen Bronson, Sixto Angulo, Veronica Acosta, Suzan Murray, Richard G. Robbins, Urs Giger, Bruce Rothschild, and Louise H. Emmons

ABSTRACT. The health status of a population of maned wolves (MW), *Chrysocyon brachyurus*, in Noel Kempff Mercado National Park (NKP), Bolivia, was studied from 2000 to 2009 by direct observations, GPS and VHF telemetry, and biomaterial collection. A total of 12 MW were anesthetized for 33 events. Causes of morbidity included severe dental disease, skin lesions, lameness, endoparasites (among them, *Dioctophyme renale* and *Dirofilaria immitis*), ectoparasites, urinary cystine calculi, traumatic injuries, and exposure to infectious disease agents. During this decade, five of the 12 (42%) MW died. Age at time of death varied from 1.5 to >10 years. Pathologic findings identified postmortem included vertebral pathology (n = 2) and severe dental disease (n = 2). The remaining seven MW either emigrated with fate unknown or were alive in 2009 and ranged in age from 8 months to 7 years. Maned wolves in NKP are geriatric by age 8 or 9. We estimated that a total of seven litters were born to three resident adults. Of these seven litters, five included at least one pup raised to 6–8 months subadults and two litters were lost, one at 16 days and the other at 5 months (Chapter 5). Our data support the observation that dental and skeletal diseases are limiting factors for the longevity of both captive and free-living MW.

Sharon L. Deem, *Institute for Conservation Medicine, Saint Louis Zoo, Saint Louis, Missouri 63110, USA;* ***Ellen Bronson,*** *Maryland Zoo in Baltimore, Druid Hill Park, Baltimore, Maryland 21217, USA;* ***Sixto Angulo,*** *Fundación para la Conservación del Bosque Chiquitano, Calle René Moreno, Santa Cruz, Bolivia;* ***Veronica Acosta,*** *Smithsonian Conservation Biology Institute, National Zoo, 1500 Remount Road, Front Royal, Virginia 22630, USA;* ***Suzan Murray,*** *Smithsonian National Zoological Park, 3001 Connecticut Avenue, Washington, D.C. 20008, USA;* ***Richard G. Robbins,*** *ISD/AFPMB, Walter Reed Army Medical Center, Washington, D.C. 20307-5001, USA;* ***Urs Giger,*** *School of Veterinary Medicine, University of Pennsylvania, 3900 Delancey Street, Philadelphia, Pennsylvania 19104-6010, USA;* ***Bruce Rothschild,*** *Department of Medicine, Northeastern Ohio Universities College of Medicine, Rootstown, Ohio 44272, USA and Biodiversity Institute, University of Kansas, Lawrence, Kansas 66045, USA;* ***Louise H. Emmons,*** *Department of Vertebrate Zoology, National Museum of Natural History, P.O. Box 37012, MRC 108, Smithsonian Institution, Washington, D.C. 20013-7012, USA. Correspondence: deem@stlzoo.org.* *Manuscript received 25 August 2010; accepted 26 August 2011.*

INTRODUCTION

One of the main goals of conservation is to evaluate and, if possible, optimize the factors that are most important for maintaining population fitness of a species. Knowing the causes of mortality and morbidity of a free-ranging species is essential to knowing how best to protect it from hazards that pose present or future threats to species survival. During our studies of the ecology of the maned wolves (MW) (*Chrysocyon brachyurus*) in Noel Kempff Mercado National Park (NKP), we took advantage of the trapping and immobilization required to deploy telemetry collars for collecting as much health information as we could under primitive field conditions. This part of our research was a major collaborative effort that over the years involved not only our field crew and four veterinarians but also the specialist knowledge of diagnostic laboratories,

parasitologists, medical entomologists, laboratory technicians, and a dentist.

Few studies have been conducted on the health of free-living MW, however, available reports include baseline hematology and chemistry profiles (Dietz, 1984; May-Júnior et al., 2009) cystinuria and cysteine calculi (Carvalho and Vasconcellos, 1995; Deem and Emmons, 2005; Dietz, 1984), descriptions of endo- and ectoparasites (Beldomenico et al., 2002; Bevilaqua et al., 1993; Carvalho and Vasconcellos, 1995; Deem and Emmons, 2005; Robbins and Deem, 2002), dental trauma (Furtado et al., 2007), and evidence of exposure to a number of infectious agents (Deem and Emmons, 2005; Deem et al., 2008). All diseases reported in free-living MW (except gunshot wounds and trauma caused by vehicle contact) are also commonly reported in captive MW, including some not yet identified in free-living individuals, such as dermatitis, proliferative gingivitis, neoplasia, and spondyloarthropathy (Fletcher et al., 1979; Hammond, 2012; Maia and Gouveia, 2002; Norton, 1990; Reid et al., 2005; Maned Wolf Husbandry Manual, 2007; Rothschild et al., 2001).

Causes of mortality of MW in captivity are similar to those reported above for morbidity. However, euthanasia (commonly elected due to pain and immobility resulting from skeletal problems) and perinatal losses account for many *ex situ* deaths (National Zoological Park, unpublished data). The majority of captive MW die by 15 years with the longest lived captive-born MW in the North American population recorded at 16 years 7 months for males and 17 years 10 months for females (M. Rodden, pers. comm.). Causes of mortality in the wild, except by vehicle road kill and shooting, are largely unknown, as is age at death. A recent study by Sollmann et al. (2009) in Emas National Park, Brazil, found survival rates of approximately 64% annually for both genders and for subadults and adults alike.

We describe what we learned of the causes of morbidity and mortality in a population of free-living MW in NKP, as an integral part of a study of their ecology. We compare our findings to causes of morbidity and mortality in captive MW at the Smithsonian Conservation Biology Institute.

Materials and Methods

Field Site

Noel Kempff Mercado National Park lies between 13°31′–15°05′S and 60°14′–61°49′W at the interface of Amazonian forest with diverse savanna ecosystems, and it includes broadleaf semi-evergreen forest, dry forest, inundated forest, dry savannas, and flood-prone savannas. The habitats and climate are described and illustrated in Chapter 1. The complex habitat mosaic of NKP results in a rich fauna of 604 bird species (B. Hennessy, Armonia, pers. comm.) and 172 mammal species, including 20 Carnivora (Emmons et al., 2006a, 2006b); all with potential to interact with MW: as prey, predators, and vectors or hosts of pathogens and parasites. The territories of the MW in our study population in Los Fierros savanna are isolated from direct contact with human settlements, pets, or livestock, except horses that travel briefly on one road a few times a year (without staying overnight or grazing). However, at least one GPS-collared maned wolf (M6) traveled 30 km to a neighboring estancia that has dogs, cats, poultry, and hoofstock and then returned into Los Fierros savanna (Chapter 3), so isolation is incomplete. There is little vehicle traffic on the single, potholed, dirt road that crosses the savanna, and we found only one maned wolf road kill, in about 1995, when there were logging trucks still speeding on that road.

Sample and Data Collection in the Field

Maned wolves were captured within NKP in wooden box traps or hardware-cloth cage-traps baited at first with live chicks, but later with sardines and fatty dried beef (see Chapter 1 for more detail). From February 2000 to July 2009, 12 MW were captured for a total of 33 anesthetic events. Immobilization was with tiletamine plus zolazepam (Telazol®, Fort Dodge Laboratories, Fort Dodge, Iowa 50501, USA; 3.5–4.5 mg/kg, intramuscular [i.m.]) or a ketamine (Ketaset®, Fort Dodge; 6–8 mg/kg, i.m.)/xylazine (Xylazine: TranquiVed, Vedco, Inc., St. Joseph, Missouri 64507; 1.1 mg/kg, i.m.) combination delivered through Telinject® plastic darts (Telinject USA Inc., Agua Dulce, California 91390, USA) using a Telinject® pistol (Bronson et al., in preparation). If needed, anesthesia was supplemented with ketamine (Ketaset®, Fort Dodge; 25–50 mg increments, intravenous or i.m.). For the ketamine/xylazine combination, the xylazine was reversed with yohimbine (Wildlife Pharmaceuticals, Inc., Fort Collins, Colorado 80522, USA; 0.125 mg/kg, i.m.).

A physical examination was performed on each maned wolf at the time of anesthesia and included temperature, pulse, respiration, detailed oral examination, detection of skin lesions, and abdominal palpation. Ages were estimated by physical characteristics (e.g., dentition, coat appearance, mammae appearance, and body measurements) according to the criteria of Dietz (1984) and in comparison

to known-aged individuals of our study. We documented with photographs the whole body, dentition, and lesions, and various samples were collected from each maned wolf. Blood was collected by venipuncture of the jugular, cephalic, or the lateral saphenous vein and was immediately placed in ethylenediaminetetraacetic acid (EDTA) anticoagulant tubes (Becton Dickinson, Franklin Lakes, New Jersey 07417, USA) and serum separator tubes (Corvac Sherwood Medical, St. Louis, Missouri 63103, USA). The sample tubes were placed in the shade until clot formation, at which point sera were separated by centrifugation (Mobilespin, Vulcan Technologies, Grandview, Missouri 64040, USA) at 3,000 g for 15 min and stored in a freezer. Alternatively, blood was allowed to clot at ambient temperature, and the serum was then decanted and kept in a cool place for 48 hours before storage in a freezer.

Blood in EDTA was used to prepare thin blood smears fixed with 99% methanol. Packed cell volumes (PCV) were determined using a portable 12 V centrifuge, and plasma total solids (TS) were measured with a handheld refractometer (Schulco, Toledo, Ohio 43608, USA) calibrated at the site. White blood cell (WBC) counts were determined manually with a prepackaged dilution system (Unopette Test 5877, Becton-Dickinson Vacutainer Systems, Rutherford, New Jersey 07070, USA). Samples were transported on dry or wet ice to the Department of Animal Health, Smithsonian National Zoological Park, USA, for storage at –70°C and laboratory testing.

Fecal samples were collected manually from the rectum and preserved in 10% formalin. Ectoparasites were collected, stored, and shipped in 70% isopropanol or ethanol. Urine was collected by cystocentesis using a 0.7mm × 25.4 mm needle, and 12 mL syringe, but not all individuals could be sampled. Urine samples were divided into aliquots and frozen in cryotubes as well as fixed in formalin. The remaining urine was evaluated using a refractometer calibrated at the site, and with Multistix-Reagent Strips for Urinalysis (Bayer Corporation, Elkhart, Indiana 46515 USA), followed by immediate centrifugation at 3,000 g for 5 min. Urine sedimentation was examined directly by microscope in the field. Preservative solutions were removed before air travel and supplemented upon arrival in the USA. All appropriate export and import permits accompanied the samples during transport and the studies were approved by the IACUC of Smithsonian National Zoological Park and Smithsonian National Museum of Natural History.

With the exception of subadults weighing <20 kg, GPS or VHF telemetry collars were placed on each maned wolf at the initial anesthetic event (see Chapter 1). On the basis of signal immobility, MW assumed dead were retrieved and any teeth or bones were collected for later evaluation. Salvaged skeletons were deposited in the Museo de Historia Natural Noel Kempff Mercado, Santa Cruz, Bolivia.

Laboratory Diagnostics

Thin blood smears were stained with a modified Wright-Giemsa stain (Hematology Three-Step Stain, Accra Lab, Bridgeport, New Jersey 08014, USA) or a Diff-Quick stain (DipQuick Stain, JorVet, Jorgensen Laboratories, Loveland, Colorado 80538, USA) and examined for blood parasites, blood cell morphology and WBC differentials. Serum biochemistries were processed on a COBAS MIRA Plus chemistry system (Roche Diagnostic Systems, Inc., Branchburg, New Jersey, 08876).

Serologic testing for antibodies was conducted at the New York State Veterinary Diagnostic Laboratory (Cornell University, Ithaca, New York) using serum neutralization for canine adenovirus (CAV-II), canine coronavirus (CCV), canine distemper virus (CDV), and canine herpesvirus (CHV); using hemagglutination inhibition for canine parvovirus (CPV); using slide agglutination/agar gel immunodiffusion for *Brucella canis*; using indirect hemagglutination assay for *Toxoplasma gondii*; and by microagglutination for *Leptospira interrogans* serovars. The same laboratory was used for detecting *Dirofilaria immitis* antigens using an occult antigen test. The five *L. interrogans* serovars tested included *L. pomona*, *L. hardjo*, *L. icterohaemorrhagicae*, *L. grippophytosa*, and *L. canicula*. Serologic testing for rabies virus was performed at Kansas State Veterinary Diagnostic Laboratory (Kansas State University, Manhattan, Kansas) using the rapid fluorescent focus inhibition test. Antibodies to *Ehrlichia canis*, *Borrelia burgdorferi*, and *Rickettsia rickettsii* were tested at the Texas Veterinary Medical Diagnostic Laboratory using an immunofluorescence assay. These serologic diagnostic tests are targeted at canine pathogens known from North America, leaving unexplored the world of native sylvatic pathogens.

Fecal samples were examined by direct microscopic examination, sodium nitrate flotation, and sedimentation methods at the New York State Veterinary Diagnostic Laboratory. One adult worm was collected perirectal and submitted to Dr. Michael Kinsella for identification. Adult ticks were identified on the basis of external morphology, using the keys of Kohls (1956) and Jones et al. (1972). Urine was assayed semiquantitatively for increased cystine concentrations using the cyanide-nitroprusside method (Shih, 1973).

Data Analyses

Results were analyzed using a commercial statistical software package (NCSS, Kaysville, Utah; SPSS, version 13.0, Chicago, Illinois). Numerical data were inspected for normality and t-tests were performed on normal data and Mann-Whitney U-tests were used where normality was rejected (Petrie and Watson, 2006). Statistical significance was determined as $p < 0.05$.

RESULTS

Among the 12 MW, seven were immobilized once, three were anesthetized two, four, and eight times, respectively, and two others were each immobilized six times. Maned wolves were generally immobilized and sampled once yearly, but a few were immobilized twice within a year at intervals of over three months. Six were male and six were female.

Physical Findings

Body weights were recorded for six females (16 measures) with a mean of 23.2 kg ± 3.6, range 17–29 kg and for six males (13 measures) as 26.2 kg ± 2.4, range 21–29 kg. Males were significantly heavier than females (t-test; $P = 0.0076$) when both age groups (i.e., subadult and adult) were combined. Body weight of adult females, based on 10 measures from three animals, was 25 kg ± 2.9, range 22.9–27.1 kg. Body weight of adult males, based on 11 measures from four animals, was 26.96 kg ± 1.64; range 23–29 kg. Adult female body weights were significantly lower than adult male body weights (t-test; $P = 0.03$).

The most striking lesions on physical examination were the dental lesions, such as abnormal conformation, wear and attrition, fractures, missing teeth, gingivitis, and caries (Table 6.1 and Figures 6.1, 6.2). Male M5 had class II brachygnathia (underbite) and several other oral lesions (Table 6.1). Other specific findings included the following: M2 was blind in the left eye due to a shrunken globe at time of anesthesia, female F3 had signs of old ear pinna trauma (probably from myiasis around an ear tag), M6 was thin with mild crepitus in multiple metatarsal joints on palpation, M8 had moderate conjunctivitis and a grade IV/VI heart murmur and was limping on release following anesthesia, F12 had a laceration on the caudal footpad, and two animals (F3, M4) had bald areas on the lateral thigh regions. Uncaptured individuals photographed by camera traps had similar ear lesions (one) and large bald areas on the thigh (one).

Hematology

Males had higher packed blood cell volumes (PCV) (37% ± 3.8) than did females (32% ± 5.3) and lower total

TABLE 6.1. Clinical and pathological dental findings for free-living maned wolves (MW) (*C. brachyurus*) in Noel Kempff Mercado National Park (NKP). Ages are estimates. Here n/a, not present; X, present.

ID	Age, Years	Abnormal conformation	Wear	Fractures	Missing teeth	Gingivitis	Gingival hyperplasia	Caries	Osteomyelitis
F1*	0.7	n/a	X	n/a	n/a	n/a	n/a	n/a	n/a
M2*	10+	n/a	X	X	X	X	n/a	n/a	X
F3	1.5–8	n/a	X	n/a	X	X	X	X	n/a
M4	0.8	n/a	n/a	n/a	n/a	n/a	n/a	n/a	n/a
M5	3–7	X	X	X	X	n/a	X	X	n/a
M6*	10	n/a	X	X	X	n/a	n/a	X	X
F7	1	X	X	n/a	n/a	n/a	n/a	n/a	n/a
M8	3–7	n/a	X	n/a	X	n/a	n/a	X	n/a
F9*	0.6–3	n/a	X	n/a	X	n/a	n/a	X	X
M10	1	n/a	X	n/a	n/a	n/a	n/a	n/a	n/a
F11*	8–10	X	X	X	X	n/a	n/a	X	n/a
F12	0.6	n/a	n/a	n/a	n/a	n/a	n/a	n/a	n/a

*Animal died during course of study. Skull was recovered for evaluation.

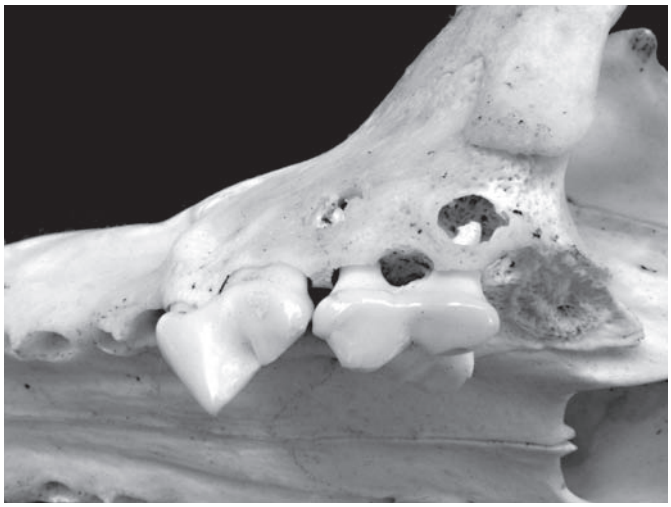

FIGURE 6.1. Upper left teeth P4 and M1 of maned wolf F9, 3 years old at death. Note that M2 was lost before death and the alveolus healed (closed), that the labial cusps of M1 are already worn flat, and that P4 shows almost no wear. P2 and P3 were lost postmortem. Osteomyelitis has eroded the bone at the root of M2. The right M2 was likewise missing. Photograph, L.H. Emmons.

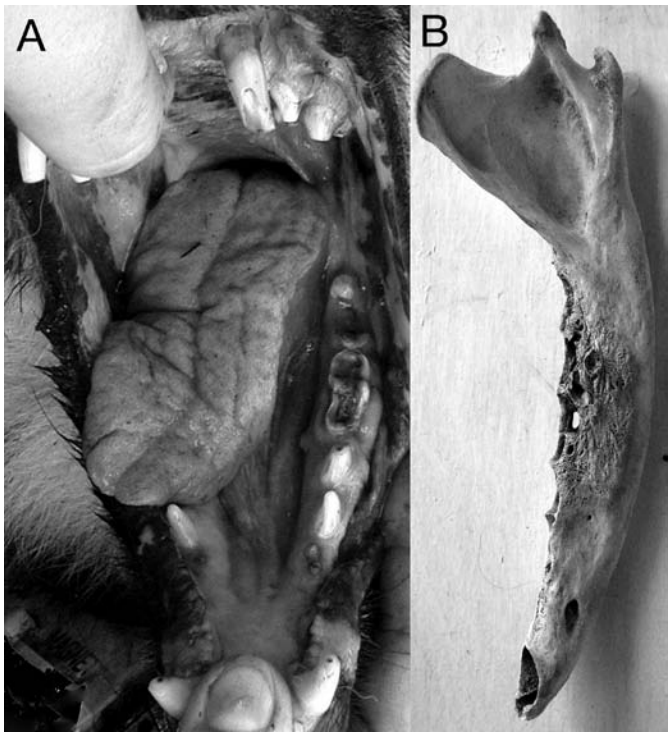

FIGURE 6.2. Teeth of geriatric male M6 with multiple dental lesions. (A) Teeth at capture including slab fracture of upper canine, other canines and premolars worn to root canals or broken off to roots, missing first lower premolars and outer upper incisors, and the broken, worn, and infected lower molars and third premolars. (B) Recovered mandible of M6, who died about 5 months after the photo in A, showing the severe bone infection underlying the cheek teeth shown in A. Photograph, L.H. Emmons.

solids (7.1 mg/dL ± 0.5) than females (7.9 mg/dL ± 0.6) (t-test; $p < 0.05$). One female (F3) had a PCV of 22% in 2007 and 2008 but had values in the normal range in other years (38% in 2005, 35% in 2006, and 31% in 2008). When we removed the two lowest PCV values (22% and both from F3), there was still a significant difference between males and females (34% ± 3.3) (t-test; $p < 0.05$). All other hematological values were not significantly different between the sexes (Table 6.2).

Serum Chemistry

Among all the parameters we measured, only the serum creatinine kinase (CK) activities differed (Mann-Whitney U-test; $p < 0.05$) between genders, with a median of 353 U/L ($n = 10$) for males and of 147 U/L ($n = 12$) for females. This may be due to the high value in one male (M5 1,310 U/L), and that both of the highest CK values were males (Table 6.3).

Serologic Testing

All 11 of the MW had antibodies to CAV-II at every sampling date ($n = 30$) with titers ranging from 512 to 4096 (Table 6.4); 85% of samples were heartworm (*D. immitis*) antigen positive and 56% tested positive for toxoplasma (*T. gondii*) antibodies. A low prevalence of antibodies to CDV, CPV, *Ehrlichia canis*, and the five serovars of Leptospira (*L. interrogens*) was found (Tables 6.4, 6.5).

Endoparasites and Ectoparasites

Eggs of endoparasites were found in all of the 14 fecal samples from the 7 MW evaluated. One adult worm, found perianally on F9, was identified as a dog roundworm (*Toxocara canis)*. Eggs of pinworms, mites, and mite eggs from the family Listrophoridae were detected in 4 samples from 3 MWs (F3, M8, and F9). All ticks identified were from the pantropical genus *Amblyomma*. Few

TABLE 6.2. Hematology for free-living MW (*C. brachyurus*) in NKP. Here n/a, not applicable.

	Male		
Measure	***N***	**Mean (SD) or median**	**Range or 10%–90% quartiles**
PCV (%)*	11	37 (3.8)	31–42
TS (mg/dL)*	11	7.1 (0.5)	6.4–8.2
WBC ($X10^3/\mu L$)	9	13,036 (6,130)	4,840–21,780
Neutrophils (%)	12	79.5	51.4–91
Bands (%)	12	0	0–2.4
Lymphocytes (%)	12	10	5–33.9
Monocytes (%)	12	2.5	0.3–12.8
Eosinophils (%)	12	1	0–8.7
Basophils (%)	12	0	0–0
	Female		
Measure	***N***	**Mean (SD) or median**	**Range or 10%–90% quartiles**
PCV (%)*	13	32 (5.3)	22–41
TS (mg/dL)*	12	7.9 (0.6)	6.9–8.8
WBC ($X10^3/\mu L$)	9	10,872 (5,937)	5,500–23,015
Neutrophils (%)	11	87	53.2–91
Bands (%)	11	0	0–2.6
Lymphocytes (%)	11	8	0–28
Monocytes (%)	11	3	0.2–10.8
Eosinophils (%)	11	1	0–22.6
Basophils (%)	11	0	0–0.8
	Both sexes		
Measure	***P* value**	***N***	**Mean (SD) or median**	**Range or 10%–90% quartiles**
PCV (%)*	0.01*	n/a	n/a	n/a
TS (mg/dL)*	0.04*	n/a	n/a	n/a
WBC ($X10^3/\mu L$)	0.46	18	11,954 (5,959)	4,840–23,015
Neutrophils (%)	0.54	23	81	56.4–91
Bands (%)	0.93	23	0	0–2.2
Lymphocytes (%)	0.19	23	10	2–26.4
Monocytes (%)	0.58	23	3	0.4–10.6
Eosinophils (%)	0.25	23	1	0–12.4
Basophils (%)	0.3	23	0	0–0

*t-test; statistical significance.

individuals had fleas and they were rare on those that did carry them (Table 6.6).

Urinary Findings

Nitroprusside test results were strongly positive for urine from two of four males and for both females tested, indicating that these MW carried the inherited disease cystinuria. Three of five urine sediments that we evaluated microscopically revealed cystine crystals. Curiously, cystine crystals were found in the urine sediment of M6, who tested negative by cyanide-nitroprusside testing. Perhaps dissolved cystine had precipitated, and only the supernatant was examined by nitroprusside testing. In contrast, urine from F3 was negative for cystine crystals by microscopy but positive by nitroprusside testing. Furthermore, ova of the giant kidney worm, *Dioctophyme renale,* were detected in three of five maned wolf samples examined by microscopic evaluation in the field (Table 6.7).

Mortality

Up to September 2009, five of the 12 MW studied died, with four deaths occurring between February and April, and three of these five were over 7 years of age (Table 6.8). Following a major fire that swept the entire area in October 2009 (Figure 1.10), two other adults disappeared (F3, M8) and were presumed dead (Chapter 5, Postscript). Examination of five retrieved skeletons revealed severe vertebral pathologies (Figure 6.3), and tooth loss and osteomyelitis of the skull in two geriatric individuals (Figures 6.1, 6.3). An exception was for elderly F11, who had molar teeth worn down to the gums, but no skeletal and only minor dental lesions: a lost premolar and a small slab fracture of a canine tooth. One female (F9), 3 years old at time of death, had an infected tooth and was positive for *D. renale* and *D. immitis* antemortem and died when the study area was experiencing unusually strong flooding. The other young female that died (F1) was believed to have succumbed to an infectious agent as the fox (*Cerdocyon thous*) population in the same section of NKP was decimated at this time.

We estimated that at least seven litters were born to three females (Chapter 5; Table 5.7). Of these, five included at least one pup raised to ≥6–8 month subadults, and two litters were lost, at 16 days (F3 in 2008) and at 5 months (unmarked mate of M2 in 2003), respectively.

TABLE 6.3. Chemistry profiles for free-living MW (*C. brachyurus*) in NKP. Here n/a, not applicable.

	Male			Female				Both sexes		
Measure	*N*	Mean (SD) or median	Range or 10%–90% quartiles	*N*	Mean (SD) or median,	Range or 10%–90% quartiles	*P* value	*N*	Mean (SD) or median	Range or 10%–90% quartiles
Glucose (mg/dL)	10	70.1 (12.8)	51–88	11	67.1 (16,7)	44–88	0.65	21	68.5 (14.7)	44–98
AST (U/L)	10	57.5	22.7–125.3	12	33.5	18.3–135.3	0.08	22	39.5	19.9–123.9
ALT(U/L)	10	85.5	25.3–350.4	12	58.5	17.9–191	0.21	22	67	24.9–214.4
ALP(U/L)	10	6	1.92–41.7	11	9	1.84	0.20	21	8	1.84–22
TP (g/dL)	10	7.26 (0.8)	5.7–8.2	12	7.66 (0.7)	6.7–8.7	0.21	22	7.5 (0.74)	5.7–8.7
Albumin (g/dL)	10	2.5 (0.5)	1.5–3.5	12	2.3 (0.4)	1.9–2.9	0.32	22	2.4 (0.5)	1.5–3.5
Globulin (g/dL)	10	4.74 (0.5)	3.9–5.5	12	5.35 (1.0)	4.2–7.0	0.96	22	5.07 (0.8)	3.9–7
BUN (mg/dL)	10	29 (14.4)	15–55	12	30.8 (10.2)	16–46	0.84	22	29.6 (12.0)	15–55
Creatinine (mg/dL)	10	1.25 (0.2)	1–1.7	11	1.2 (0.3)	0.9–1.7	0.83	21	1.2 (0.2)	0.9–1.7
Phosphorus (mg/dL)	10	4.2	3.6–6.6	11	4.3	3.3–7.6	0.92	22	4.25	3.53–6.67
Calcium (mg/dL)	10	8.51 (0.97)	6.7–10.2	11	8.54 (0.45)	7.9–9.3	0.94	22	8.5(0.7)	6.7–10.2
Sodium (mmol/L)	10	147.5	127.9–156.8	12	146	140.3–154.4	0.43	22	146.5	140.3–155
Potassium (mmol/L)	11	4.4	4.12–7.12	11	4.3	3.94–4.76	0.13	21	4.4	4.1–4.88
Chloride (mmol/L)	10	121.5	101.4–124.9	12	117	106.9–125.2	0.16	22	118	106.9–124.7
Bilirubin (mg/dL)	10	0.3	0.2–0.49	12	0.3	0.2–0.4	0.68	22	0.3	0.2–0.4
CK (U/L)*	10	352.5	136.6–1310.2	12	146.5	50.9–520.3	0.01*	n/a	n/a	n/a

*Mann-Whitney U-test; statistical significance.

DISCUSSION

Physical Condition

The 12 MW we evaluated in NKP over a 10-year study period included equal numbers of males and females and ranged in age from 0.6 to over 10 years. The sex and age structure suggest juvenile recruitment into the population, although three of seven observed litters had no successful pups reared. Body weights for the MW in our study were less than those for MW in a recent study in Brazil (May-Júnior et al., 2009). The difference in body weight could be related to food availability as individuals lost weight coincident with a decline in rodents (Emmons, 2009; Chapter 4; Figure 4.3).

The most significant physical findings in live-captured MW were associated with dental disease (Figures 6.1, 6.2). Many individuals had lesions consistent with caries, which could be caused by the high quantities of sugars and acids from fruits in the diet (Chapter 4; Bestelmeyer, 2000; Dietz, 1984; Motta-Junior et al., 1996). Many MW had evidence of traumatic injuries to their teeth (slab fractures). This is consistent with findings from free-living MW in Brazil (Furtado et al., 2007) and captive MW (Hammond, 2012). Although we did not see the degree of gingival hyperplasia commonly seen in captive MW in the 1980s and 1990s in North America (Norton, 1990), three MW had some evidence of gingival hyperplasia.

Other clinical findings included probable traumatic injuries (e.g., blind left eye and split lower lip and eyelid in M2 and paw lesion in F12) and possibly infectious agents (e.g., conjunctivitis in M8). Additionally, the IV/VI heart murmur in this individual (M8) may have been associated with heartworm infestation as he consistently tested high positive to *D. immitis* antigen. M8 also demonstrated persistent weight-bearing lameness over 3 years and a slow recovery after one anesthetic event. A diagnosis for the cause of the alopecia in the hindquarters of three youngsters, seen only in 2002–2003, was not determined but most likely was due to parasitic or traumatic events.

One blood sample was removed from the data set for hematology and chemistry analyses as values from this sample were not consistent with life, and thus improper sample handling was suspected. Only PCV and TS differed

TABLE 6.4. Test results for selected parasitic and pathogenic agents of free-living MW (*C. brachyurus*) in NKP. CAV-II, canine adenovirus; CCV, canine coronavirus; CDV, canine distemper virus; CHV, canine herpesvirus; CPV, canine parvovirus; ND, no data.

ID	Date	*Leptospira ictero*	*L. grippophytosa*	CAV-II	CCV	CDV	CHV	CPV	*Dirofilaria immitis*	*Toxoplasma gondii*	Rabies	*Ehrlichia canis*	*Rickettsia rickettsii*	*Borrelia burgdorferi*
F1	15 Feb 00	0	0	512	0	0	0	10	Positive	0	0	ND	ND	ND
M2	20 Oct 01	0	0	512	0	12	0	10	0	0	0	ND	ND	ND
F3	7 Oct 03	0	0	512	0	12	0	10	0	0	0	ND	ND	ND
F3	9 Oct 04	0	0	1536	0	12	0	40	0	256	16	ND	ND	ND
F3	2 Oct 05	0	100	1024	8	16	0	0	0	512	0	80	Positive	0
F3	4 Sep 06	0	0	256	0	0	0	0	Positive	256	0	0	64	0
F3	21 Sep 07	0	0	2048	8	0	0	0	0	ND	0	0	256	ND
F3	15 Jul 08	0	0	4096	0	0	0	0	Suspicious	ND	0	320	0	ND
F3	19 Oct 08	0	0	768	0	0	0	0	Low	180	0	80	64	0
M5	4 Oct 04	0	0	1024	0	24	0	20	High	128	13	ND	ND	ND
M5	28 Sep 05	0	0	512	0	0	8	0	High	128	0	80	Positive	0
M5	29 Jan 07	0	0	384	0	0	0	0	High	256	0	0	0	0
M5	26 Jul 07	200	0	4096	0	0	0	0	High	ND	0	80	0	ND
M5	16 Jul 08	200	0	768	0	0	0	80	0	ND	0	0	0	ND
M6	27 Sep 05	0	0	1024	0	8	0	0	Positive	512	0	80	Positive	0
F7	21 Oct 05	0	0	1024	0	8	0	0	0	128	0	80	Positive	0
M8	25 Oct 05	0	0	512	0	0	0	0	High	128	0	80	Positive	0
M8	5 Sep 06	0	0	512	0	0	0	0	High	128	0	0	64	184
M8	25 Jul 07	0	0	1024	0	0	0	0	High	ND	0	80	0	ND
M8	8 Jul 08	0	0	2048	0	0	0	0	High	ND	0	0	0	ND
M8	22 Oct 08	0	0	768	0	0	0	0	High	180	0	320	64	0
M8	7 Jul 09	0	0	3072	0	0	0	0	High	180	ND	80	64	0
F9	4 Sep 06	ND	ND	512	0	0	0	0	Low	128	ND	0	256	242
F9	18 Jul 07	0	0	4096	0	0	0	0	Positive	ND	0	0	256	ND
F9	7 Jul 08	0	0	768	0	0	0	0	0	ND	0	80	256	ND
F9	12 Oct 08	0	0	2048	0	0	0	0	High	60	ND	80	ND	120
M10	16 Sep 06	ND	ND	512	0	0	0	0	0	64	ND	0	256	25
F11	4 Feb 07	ND	ND	192	0	0	0	0	High	256	ND	80	0	161
F11	18 Jul 07	0	0	1024	0	0	0	0	High	ND	0	0	0	ND
F12	16 Oct 07	0	0	2048	0	0	0	0	0	ND	0	0	256	ND
Total Animals		1/11 (9%)	1/11 (9%)	11/11 (100%)	1/11 (9%)	5/11 (45%)	1/11 (9%)	4/11 (36%)	7/11 (64%)	8/10 (80%)	2/10 (20%)	7/9 (78%)	8/9 (89%)	4/8 (50%)
Total Samples		2/27 (7%)	1/27 (4%)	30/30 (100%)	2/30 (7%)	7/30 (23%)	1/30 (3%)	6/30 (2%)	20/30 (67%)	17/20 (85%)	2/25 (8%)	14/25 (67%)	16/24 (67%)	5/15 (33%)

TABLE 6.5. Comparison of seroprevalence of selected parasitic and pathogenic agents of free-living MW (*C. brachyurus*) in the NKP and domestic dogs on the perimeter.

Animal	*Dirofilaria immitis*	*T. gondii*	Rabies	CAV-II	CHV	CDV	CPV	CCV	*Leptospira*	*E. canis*	*R. rickettsii*	*B. burgdorferi*
MW	7/11	8/10	2/10	11/11	1/11	5/11	4/11	1/11	2/11	8/9	8/9	4/8
(*n* = 11)	(64%)	(80%)	(20%)	(100%)	(9%)	(45%)	(36%)	(9%)	(18%)	(89%)	(89%)	(50%)
Dog*	13/40	32/40	22/39	7/40	28/40	37/40	34/40	3/40	8/40	19/22	19/22	0/22
(n = 40)	(33%)	(80%)	(56%)	(18%)	(70%)	(93%)	(85%)	(8%)	(20%)	(86%)	(86%)	(0%)
P value	NS	NS	0.04	<0.001	<0.001	<0.001	0.003	NS	NS	NS	NS	0.003

*Data from Bronson et al. (2008). Here NS, not significant.

TABLE 6.6. Ecto- and endoparasites of free-living MW (*C. brachyurus*) in the NKP.

Parasites	Males	Females
Endoparasites (eggs)		
Ancylostoma caninum	1	1
Ancylostoma sp.	3	2
Ascarid-like egg (avian)	0	1
Capillaria aerophilia	3	3
Capillaria sp.	4	2
Coccidia	0	1
Diphyllobothrium sp.	2	1
Fluke-like eggs	1	0
Gnathostoma sp.	0	1
Isospora sp.	1	0
Mite and mite eggs (Family Listrophoridae)	3	2
Physaloptera sp.	2	0
Pinworm eggs	3	2
Strongyle-like egg (avian)	0	2
Trichuris sp.	3	1
Toxocara canis	0	1 adult
Ectoparasites		
Amblyomma sp.	14	6
Amblyomma ovale	4	0
Amblyomma cajennense	6	2
Amblyomma pecarium	0	1
Amblyomma tigrinum	6	5
Amblyomma triste	4	3
Mallophaga (chewing lice)	1	0
Rhopalopsyllus australis spp. (flea)	0	1

TABLE 6.7. Results from urinary testing in free-living MW (*C. brachyurus*) in NKP. Here n/a, not available.

Identification (no. of samples)	Laboratory	Microscope
F1 (1)	n/a	No crystals; *Dioctophyme renale* ova
F3 (1)	Positive	No crystals; *D. renale* ova
M5 (3)	Positive	Crystals (3/3); *D. renale* ova (2/3)
M6 (1)	Negative	Crystals; no ova
M8 (1)	Positive	n/a
M10 (1)	Negative	n/a
F11 (1)	Positive	Crystals; no ova

between our male and female MW. Females had significantly lower PCV and higher TS values than males. One possible explanation for this difference was a chronic underlying infectious process in the females, which may have been responsible for the two low (22%) values for F3. Packed cell volume values in both male and female MW in our study were lower than both those for captive MW in North America, with values of 40.9 % ± 6.5 (sample size of 132 animals and 579 points) (International Species Information System [ISIS], 2002), and for free-ranging MW tested in Brazil (about 40%; May-Júnior et al., 2009).

On chemistry profile, only CK differed between males and females in our study, with males having a higher median value. This may be due to the high value in one male

TABLE 6.8. Findings from five MW (*C. brachyurus*) that died in the NKP during our study period of February 2000–July 2009.

Wolf	Date	Age	Cause(findings)
F1	March–Oct. 2000	Young (8 mo)	Disease epidemic?
M2	Feb. 2004	Old	Date of death during flooding in study area. Changes consistent with geriatric status. Most severe vertebral pathology lesions of all MW we have examined. Maxillary osteomyelitis. Multiple tooth loss.
M6	Jan. or Feb. 2006	Old	Date of death during flooding. Changes consistent with geriatric status. Many teeth missing with lytic bone surrounding, mandibular osteomyelitis, osteoporosis, vertebral pathology.
F9	16 April 2009	3 years	Date of death during flooding. Osteomyelitis of maxillae, zygomatic arch.
F11	22 March 2008	10 years	Date of death during flooding. There were no obvious bony lesions. Molars worn to gums. This female was small in stature.

FIGURE 6.3. Vertebrae of M6 showing severe bridging spondyloarthropathy. Photograph, L.H. Emmons.

(M5) (1,310 U/L) and the fact that both of the highest CK values were from males. Interestingly, in the Brazil study, there was also a difference in CK between males and females, with females having higher values than males (May-Júnior et al., 2009).

A number of differences were evident between chemistry profile results of our NKP MW and those in captivity and free-living MW in Brazil. The glucose mean value (68.5 mg/dL) in Bolivian MW was significantly lower than the ISIS value (114 mg/dL ± 25) and the value for MW in Brazil (106.4 mg/dL ± 5.0) (ISIS, 2002; May-Júnior et al., 2009). The glucose value in the MW of this study was low for a carnivore and warrants further investigation.

Serology and Endoparasites

Maned wolves in NKP were seropositive for parasitic and infectious diseases of concern in carnivore conservation, and known to cause high morbidity and mortality in captive MW. Our original hypothesis was that domestic dogs living at the perimeter of the park were the likely route of exposure for these MW. However, we did not find

support for this, because high seroprevalence was found in MW for a number of pathogens that were at low prevalence in domestic dogs near the park (Table 6.5; Bronson et al., 2008). In 40 domestic dogs around NKP, seroprevalences were high for CDV (93%), CHV (70%), CPV (85%), *T. gondii* (80%), and *E. canis* (86%) (Bronson et al., 2008). In these dogs, CAV-II prevalence was low at 18% as compared to the 100% prevalence in the MW. Because the dogs were short lived and all young, their disease profiles may reflect short exposure times and be highly variable from one year to the next. We recommend further studies that include longer-term sampling and molecular testing for virus typing to determine the relationship between the viruses within the maned wolf and domestic dog populations.

All MW were seropositive for CAV-II with titers waxing and waning during the 10 year study period. Canine adenovirus is a known cause of pup mortality in captive MW (Barbiers and Bush, 1995) and is suspected to have caused hepatitis in one individual (Hammond, 2012). Although we cannot confirm an association based on these data, it is interesting to note that in the years when F3 (2008) and F11 (2007) had high adenovirus titers (4096 and 1024, respectively), neither had successful litters. The mate of F3 (M8) also had a CAV-II titer change from 768 (in 2008) to 3072 (in 2009). This litter died at about 16 days postpartum (August 2008), based on F3's abrupt cessation of movement behavior associated with lactation (Chapter 5).

Seven of the 11 MW tested were positive for the antigen of *D. immitis*, the causative agent of canine heartworm. This is a potentially fatal, mosquito-borne disease of domestic and wild carnivores. In captivity, MW are often maintained on a heartworm prophylactic because of the devastating effect of this parasite. The role of *D. immitis* in morbidity and mortality of free-ranging MW is not known, although one of the MW (M8) had high positive antigen to *D. immitis* and an IV/VI heart murmur during anesthetic events. At the beginning of our study in Los Fierros pampa, geriatric M2 was negative for *D. immitis* (2001), while F3 on the same territory, who was sampled yearly from 2003, was seronegative until she was four. At 5 years she had converted to antigen positive status, 2 years after acquiring a highly-positive mate (M5). Of six animals tested less than 1 year of age, four were antigen negative and two were already positive, one less than 6 months old, born of positive parents. All four adults captured for the first time after 2004 were antigen positive. This suggests an increase during our study to 100% adult prevalence. Thirty-three percent of the domestic dogs tested were also positive to *D. immitis* (Bronson et al., 2008). It is possible that a dog-mosquito-wild carnivore endemic cycle operates in the NKP region of Bolivia, but our data also suggest that currently heartworm may circulate between the MW and mosquitoes.

Many of the MW were positive for *T. gondii*, as in a study of captive MW in Brazil (Vitaliano et al., 2004). This is not surprising for a species that eats positive prey (rodents and other small mammals; Deem et al., 2009) and is sympatric with seven native felid species (the definitive host).

Free-ranging Canidae usually harbor enteric parasites (Kennedy-Stoskopf, 2003), including those found in the MW in this study. These parasites are not often present in high numbers and do not cause a clinical problem in healthy adult free-living canids. However, in animals immunocompromised because of factors such as concurrent disease or physiologic stress related to habitat or population modifications, enteric parasites may result in disease. The lungworm *Capillaria aerophila*, detected in the feces of six MW in this study, can cause clinical signs associated with bronchitis and pneumonia, but these animals had no overt respiratory signs. Eggs of pinworms, mites, and mite eggs from the rodent-specific family Listrophoridae were detected in three MW, probably ingested with their rodent prey (Chapter 4). Likewise, ascarid-like and strongyle-like eggs from bird parasites were found in three MW, indicating ingestion of avian prey. A tapeworm, likely *Spirometra* spp., also associated with rodents, was recovered from maned wolf feces in the savanna (Mike Kinsella, pers. comm.). One adult worm, *Toxocara canis*, was identified in a female maned wolf (F9) approximately 6 months prior to her death around 3.5 years of age. On postmortem evaluation, there was evidence of severe osteomyelitis of the skull, believed to be from a tooth infection (Figure 6.1). Thus F9 possibly succumbed to sepsis, confounded by heartworm and gastrointestinal parasite infestation.

Ectoparasites

Of the five definitively identified tick species collected during this study, only *Amblyomma cajennense*, which we earlier reported from the maned wolf (Robbins and Deem, 2002), is known to be of veterinary importance. This tick has been found infected with *Encephalitozoon*-like microsporidia (Barbosa Ribeiro and Guimarães, 1998) and, together with its congeners, may be a vector of filarial worms, such as *Yatesia hydrochaerus*, which is specific to capybaras (Yates and Lowrie, 1984). *Amblyomma cajennense* also causes paralysis in bovine, ovine, and caprine hosts in Brazil (Serra-Freire, 1983). In the

medical literature, *A. cajennense* is recognized as the principal vector of so-called Rocky Mountain spotted fever in the Neotropics, and, given its vast range and propensity for attacking humans, is a known or suspected vector of arboviruses, Chagas disease, and even leprosy (Guglielmone et al., 2003). We note that eight of nine tested MW were positive for *Rickettsia rickettsii* (Rocky Mountain spotted fever; but the antisera may cross-react with a local variant).

Amblyomma spp. ticks were previously reported from free-living MW (Dietz, 1984); but the first documented *A. ovale* was from our study population (Robbins and Deem, 2002). In Brazil, *A. ovale* has been implicated as a vector of *Rickettsia parkeri*, strain Atlantic rainforest, a novel spotted fever agent pathogenic to humans (Sabatini et al., 2010). *Amblyomma pecarium* is an uncommonly collected parasite of Artiodactyla known from Mexico, Panama, and Bolivia (Fairchild et al., 1966; Robbins et al., 1998). It might occasionally transfer to carnivores that prey on these herbivores or their carrion. *Amblyomma tigrinum* adults are highly specific to wild and domestic carnivores, so its occurrence on a maned wolf is expected. Adult stage *Amblyomma triste* likewise parasitize carnivores. Our records (4♂, 3♀; Table 6.6) from NKP are the first for Bolivia.

Urinary Health

Morbidity from the genetic disease cystinuria, and resulting cystine calculi with urinary blockage, has been a common problem estimated to affect up to 80% of both wild and captive MW and led to nutritional modifications to minimize the occurrence of these calculi among captive MW in the United States (Bovee et al., 1981; Fernandes and Marcolino, 2007; Norton, 1990). Similarly, 71% of MW we tested (n = 7) were cystinuric, but we found no evidence of cystine calculi or urinary blockage. This agrees with another study in a free-living maned wolf population (Dietz, 1984). An ancient mutation and founder effect has been proposed (Bovee et al., 1981; Dietz, 1984; Fernandes and Marcolino, 2007; Norton, 1990), and mutations in the renal basic amino acid transporter have been identified in Newfoundland and Labrador retriever dogs with type I cystinuria and an autosomal recessive trait. However, there are many other breeds with type I and non–type I cystinuria (only males are cystinuric) where the molecular defect has not yet been defined. Initial studies of MW did not identify a mutation in the renal basic amino acid transporter (Kehler et al., 2002). With the recent completion of the full canine and low-density wolf genome sequences, progress can be made in MW. Samples have been preserved for future DNA studies.

Our finding of *D. renale* ova in three MW was not surprising, as this parasite is a common pathogen of recently captive MW (Kumar et al., 1972). *Dioctophyme renale* is often associated with a hypoplastic right kidney in infected MW and could contribute to mortality, especially with concurrent disease (Kumar et al., 1972; Norton, 1990).

Mortality

Forty-two percent (5/12) of the MW in our study died before September 2009, with deaths throughout the study years. This mortality rate is similar to that recorded in Emas National Park, where the survival rate was estimated at 64% per year for all age classes (Sollmann et al., 2009). All deaths at Los Fierros occurred between February and April, the months of flooding when foraging and movement in the study area are limited and could contribute to poor nutrition, debilitation, and death. The fates of the two individuals that vanished after the October 2009 fire are uncertain, as they could have escaped to die elsewhere. One was about 8 years old (F3) and the other 7 years old (M8), the latter in good health but the former geriatric, with severe dental problems. One yearling female survived the fire and was alive in 2011 (Chapter 5, Postscript).

Three of the five (60%) MW that died before September 2009 were estimated at 8 to >10 years old and considered geriatric at the time of death. Two of these three (67%) had severe spondyloarthropathy. This pathologic finding was previously considered a disease of captivity, with an incidence of about 80% of geriatric captive MW (Elizabeth Hammond, pers. comm.; Rothschild et al., 2001). The two affected MW in our study (M2 and M6) had the most severe skeletal lesions among any of three wild-taken and seven zoo skeletons (NZP) evaluated at the National Museum of Natural History (evaluated by LHE). The one geriatric maned wolf (F11) with no vertebral lesions was unusually small (22 kg). We conjecture that the body structure of MW (e.g., long legs and short back) and hunting style, of pouncing on small prey, make MW prone to vertebral pathologies. Further investigation is needed into this pathologic condition of captive and free-living MW. The two animals with severe vertebral lesions had likely lived with the condition for years.

Three of the MW that died had indication of severe osteomyelitis of the maxillae (M2, F9) or mandible (M6; Figure 6.2B) that was most likely associated with a tooth root abscess. M6 was geriatric at the time of death and had evidence that osteomyelitis had spread into the postcranial

skeleton. However, F9 was only 3 years old but had evidence of spread of infection into the adjoining zygomatic arch, above and below the eye (Figure 6.1). This female died when the study area was experiencing unusually prolonged and deep flooding, and we hypothesize that the oral infection and associated pain decreased appetite while flood waters made finding food difficult. Prior to death she traveled from her own flooded territory into the drier adjacent territory, where she may have also experienced social conflict and stress. These two factors, in addition to her positive status for *D. renale* and *D. immitis*, may have led to poor nutrition and possible sepsis as the proximate and definitive cause of death. The other young maned wolf that died (F1) was believed to have succumbed to an infectious agent, as the fox (*Cerdocyon thous*) population in the same section of NKP was also decimated at this time.

Necropsy results of 47 MW housed at the Smithsonian Conservation Biology Institute, Front Royal, Virginia, from 1975 to 2003, list the primary cause of death as follows: 17 perinatal, two urolithiosis (cystine calculi), three infectious agents (e.g., CDV, CPV, and *Escherichia coli*), one trauma, three digestive, one cardiomyopathy, and 19 euthanasias. The reasons stated for euthanasia included four neoplasia, two infectious (one pyometra and one rabies virus), one trauma, four kidney related (two of these were urolithiasis), two spondylosis, one postsurgical, one cull, one arthritis, two old age, and one digestive problems. Thirteen of these 19 (68%) euthanized MW were >10 years old at time of euthanasia, and there were 11 males and 8 females.

CONCLUSIONS

We found a surprising number of significant clinical and pathologic findings in this small population of free-living MW in Bolivia. The NKP maned wolf population was previously estimated at 120 pairs (Rumiz and Sainz, 2002), but we now believe it is closer to 20–30 pairs (see Chapter 3). On the basis of our findings for the 12 MW in our study, the health of the Los Fierros population may be rated as only moderate. The lower body weights, PCV, and glucose values compared to other maned wolf populations, as well as the many dental abnormalities, may indicate a lower plane of nutrition in this population. Recent evidence of rodent population declines indicates that the prey base for this population of MW declined over 94% in biomass during the study (Chapter 4; Emmons, 2009).

We had not anticipated such a high number of dental and bony lesions. The prevalence of dental disease was most likely associated with the dietary intake of acidic, sweet fruits such as *Alibertia edulis* and *Solanum gomphodes* (Chapter 4), and tooth fractures related to chewing fruits with hard stones and perhaps armadillos. The high prevalence of vertebral pathologies in the older MW that died was similar to that found in captive populations and may suggest that this pathology is more a function of body structure and behavior than a disease of captivity as previously thought (Rothschild et al., 2001).

Although there is no definitive diagnosis for the cause of death in the one maned wolf (F1) that died at less than 1.5 years of age; a concurrent large decline in crab-eating foxes implicates an infectious disease epidemic. We therefore recommend continued domestic dog health monitoring, domestic animal vaccination, and enforcement of the prohibition of all domestic animals within the park, especially of carnivores.

Our ability to conserve the growing number of endangered species will necessitate an understanding of the health of both captive and free-living populations. We anticipate that studies similar to this one will provide data necessary for the long-term conservation of animals in their natural habitats and proper captive care and propagation of endangered species in captivity.

Acknowledgments

We thank Dr. Michael Kinsella for tapeworm identification, Dr. Ira Luskin for interpretation of dental pathologies, Dr. Edward Dubovi for laboratory assistance, and Melissa Rodden for kindly providing data from the captive breeding program at the Smithsonian Conservation Biology Institute. Thanks also to Dr. Michael W. Hastriter and Dr. Robert M. Timm for lice identification.